

Head-and-neck squamous cell carcinoma patients with CT taken during pre-treatment, mid-treatment, and post-treatment (HNSCC-3DCT-RT)

Summary

Researchers will have the unique opportunity to visualize how head-and-neck squamous cell carcinoma (HNSCC) patients' 3D CT image data changes with radiotherapy between pre-treatment, mid-treatment, and post-treatment. They will also have the advantage to receive additional information such as a) photon energy, b) number of arcs for volumetric modulated arc radiotherapy (VMAT) therapy, c) tumor volume and location, d) CT-to-density table, e) treatment related toxicities for parotid glands and oral cavity, f) patient age and weight, patient chemotherapy medication, g) prior surgery, h) performance status, i) histology, j) disease stage, k) number of targets, l) organs at risk, and m) other structures delineated on the CT image.

This data collection contains three dimensional high-resolution (3D) fan-beam CT scans collected during pre-treatment, mid-treatment, and post-treatment using a Siemens 16-slice CT scanner with standard clinical protocol for 31 head-and-neck squamous cell carcinoma (HNSCC) patients. Patients underwent radiotherapy treatment to a total dose of 58-70 Gy, using daily 2-2.20 Gy, fractions for 30-35 fractions. The pre-treatment planning CT scans were performed with a median of 13 days (range: 2-27) before treatment, the mid-treatment CT was performed at fraction 17 (range: 8-26), and the post-treatment CT around fraction 30 (range: 26th fraction - 21 weeks post treatment). In addition to the imaging data, the data sets contain contours of anatomical structures for radiotherapy. The contours were generated by the attending radiation oncologists for treatment planning purposes, and subsequently treatment plans were generated with Eclipse® (Varian Medical Systems, Inc., Palo Alto, CA) treatment planning system. In addition to CT image data, included are: a) photon energy, b) number of arcs for volumetric modulated arc radiotherapy (VMAT) therapy, c) tumor volume and location, d) CT-to-density table, e) treatment related toxicities for parotid glands and oral cavity, f) patient age and weight, patient chemotherapy medication, g) prior surgery, h) performance status, i) histology, j) disease stage, k) number of targets, l) organs at risk, and m) other structures delineated on the CT image.

All patients were recruited according to the following criteria. Inclusion: i) patients had histologically confirmed head-and-neck tumors, ii) were treated with definitive radiation therapy or concurrent chemoradiation therapy, iii) patients treated with post-operative radiation therapy, for whom the gross tumor volume (GTV) or the resection cavity were visible on CT, such that it could be delineated as a target for radiotherapy, iv) patients were informed of the investigational nature of this study and were able to understand and to sign a written informed consent document.

Exclusion: i) pregnant or nursing women were not eligible to participate, ii) women of reproductive potential must have been offered a pre-treatment pregnancy test and informed of the need to practice an effective contraceptive method, iii) patients younger than 18 years, and iv) patients whose size and weight would not allow CT scanning.

Acknowledgements

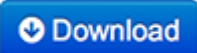

The research was funded in large part by the NIH grant R01CA163370.

For scientific inquiries about this dataset, please contact the investigators through the TCIA Helpdesk: help@cancerimagingarchive.net

Data Access

Data Access

Click the **Download** button to save a ".tcia" manifest file to your computer, which you must open with the [NBIA Data Retriever](#). Click the **Search** button to open our Data Portal, where you can browse the data collection and/or download a subset of its contents.

Data Type	Download all or Query/Filter
Images and Radiation Therapy Structures (DICOM, 14GB)	 

Clinical Data (xlsb, 34kb)


Detailed Description**Detailed Description**

Collection Statistics	
Modalities	CT, RTDOSE, RTSTRUCT
Number of Participants	31
Number of Studies	94
Number of Series	372
Number of Images	18906
Image Size (GB)	14.4

Citations & Data Usage Policy**Citations & Data Usage Policy**

This collection is freely available to browse, download, and use for commercial, scientific and educational purposes as outlined in the [Creative Commons Attribution 3.0 Unported License](#). See TCIA's [Data Usage Policies and Restrictions](#) for additional details. Questions may be directed to help@cancerimagingarchive.net.

Please be sure to include the following citations in your work if you use this data set:

i Data Citation

Tatiana Bejarano, Mariluz De Ornelas Couto, Ivaylo B. Mihaylov. (2018). Head-and-neck squamous cell carcinoma patients with CT taken during pre-treatment, mid-treatment, and post-treatment Dataset. The Cancer Imaging Archive. <http://doi.org/10.7937/K9/TCIA.2018.13upr2xf>

i TCIA Citation




Clark K, Vendt B, Smith K, Freymann J, Kirby J, Koppel P, Moore S, Phillips S, Maffitt D, Pringle M, Tarbox L, Prior F. **The Cancer Imaging Archive (TCIA): Maintaining and Operating a Public Information Repository**, Journal of Digital Imaging, Volume 26, Number 6, December, 2013, pp 1045-1057. ([paper](#))

Other Publications Using This Data

TCIA maintains [a list of publications](#) which leverage our data. At this time we are not aware of any publications based on this data. If you have a publication you'd like to add please [contact the TCIA Helpdesk](#).


Versions**Version 2 (Current) Updated 02-06-2019**

Data Type	Download all or Query/Filter

Images (DICOM, 14GB)	 
	(Requires the NBIA Data Retriever .)
Clinical Data (xlsb, 34kb)	

Added clinical data and removed one series from the Collection.

Version 1 Updated 08-30-2018

Data Type	Download all or Query/Filter
Images (DICOM, 14GB)	
	(Requires the NBIA Data Retriever .)