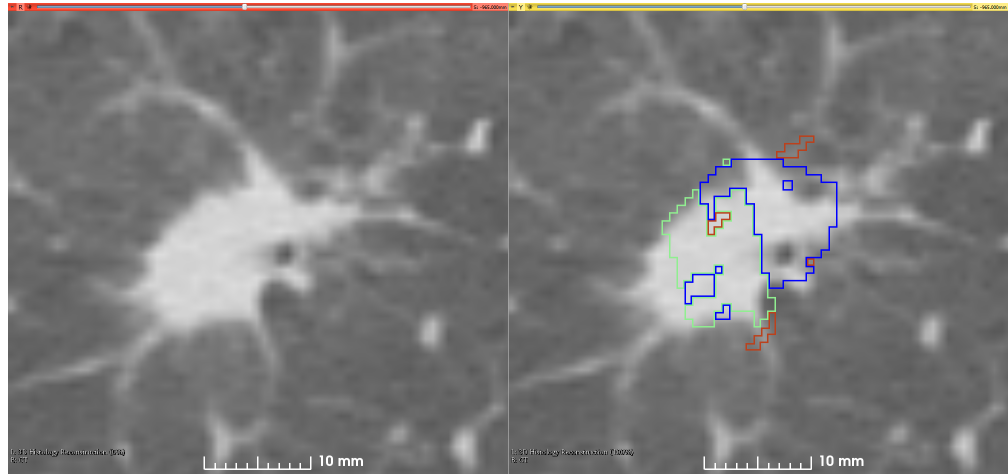


Lung Fused-CT-Pathology

Summary

This is the first attempt of mapping the extent of Invasive Adenocarcinoma onto *in vivo* lung CT. The mappings constitute ground truth of disease and may be used to further investigate the imaging signatures of Invasive Adenocarcinoma in ground glass pulmonary nodules. Patient with small ground glass nodules with >2 histology



slices per nodule were included. Patients with solid large nodules (>40mm), with <3 histology slices or with histology slices showing substantial artifacts were excluded from this study (see reference below for details). Data collection and analysis was provided by Case Western Reserve University.

References

- All the program scripts that were used for generating the results and data in this paper have been made available at <https://github.com/mirabelarusu/RadPathFusionLung>
- This study is described in detail in the following publication:
 - Rusu M., Rajiah P., Gilkeson R., Yang M., Donatelli C., Thawani R., Jacono F.J., Linden P., Madabushi A. (2017) Co-registration of pre-operative CT with ex vivo surgically excised ground glass nodules to define spatial extent of invasive adenocarcinoma on *in vivo* imaging: a proof-of-concept study. *European Radiology* 27:10, 4209:4217. DOI: <https://doi.org/10.1007/s00330-017-4813-0>

Data Access

Data Access

Click the **Download** button to save a ".tcia" manifest file to your computer, which you must open with the [NBIA Data Retriever](#). Click the **Search** button to open our Data Portal, where you can browse the data collection and/or download a subset of its contents.

Data Type	Download all or Query/Filter
Images (DICOM, 5.5 GB)	Download Search
Annotated Whole Slide Pathology Images (TIF, 21.3 GB)	Download
Clinical data (XLSX)	Download

Click the Versions tab for more info about data releases.

Detailed Description**Detailed Description**

Collection Statistics	Radiology Image Statistics	Pathology Image Statistics
Modalities	CT, Histology compartments mapped on CT (DICOM)	Pathology
Number of Participants	6	6
Number of Studies	6	6
Number of Series	52	N/A
Number of Images	11,210	25
Image Size (GB)	5.5	21.3

Supporting Documentation

Within the directory CT_Segmentations_and_annotations/CT_Segmentations/<ptID>/ there are five directories:

1. BloodVessels (derived from CT)
2. Nodule (derived from CT)
3. MappedFromHistologyBloodVessels
4. MappedFromHistologyInvasion
5. MappedFromHistologyLesion

The data set is fully described in the following publications:

Rusu et al. Co-registration of pre-operative CT with ex vivo surgically excised ground glass nodules to define spatial extent of invasive adenocarcinoma on in vivo imaging: a proof-of-concept study. European Radiology (2018); PMID: PMC5630490 DOI:[10.1007/s00330-017-4813-0](https://doi.org/10.1007/s00330-017-4813-0)

Histology Data Description

There is one folder for each patient, with the same folder name as the TCIA ID. Each folder with TCIA ID name contains 2 folders:

- “images”
 - Contains scanned histology images (in tiff format) pertinent to the TCIA ID Patient, e.g. LungFCP-01-0001_b1.tiff, LungFCP-01-0001_b2.tiff, etc
- “annotations”
 - Contains the pathologist’s annotations, stored as tiff file with the same image size as the scanned histology files, with 0 where there is not label, and 255 where a region was annotated. It is possible to have multiple annotations for each file, e.g. for file LungFCP-01-0001\images\LungFCP-01-0001_b1.tiff the following regions are available:
 - LungFCP-01-0001_b1_annotation_00_R000G255B000.tiff
 - LungFCP-01-0001_b1_annotation_00_R255G000B000.tiff

A part of the filenames (LungFCP-01-0001_b1_annotation_00_RxxxGyyyBzzz) indicate the type of annotation:

- Adenocarcinoma in Situ : R000G000B255, R001G000B255, R002G000B255
- Invasive Adenocarcinoma: R000G255B000, R001G255B000, R002G255B000, R003G255B000, R004G255B000, R005G255B000, R006G255B000

- Invasive Adenocarcinoma + Adenocarcinoma in Situ: R255G000B000

If multiple files are available for the same type of annotation, e.g. Invasive Adenocarcinoma, it indicates that the pathologists has annotated multiple regions

Description of the content of “FinalPublishedResults” folder

The folder “FinalPublishedResults” contains one folder for each patient. Within each patient folder, there are 3 subfolders: “CT”, ”Histology”, & ”Results_XX”. When expanded each patient folder appears as depicted below.

- LungFCP-01-0001
 - CT
 - Histology
 - Results_XX
- LungFCP-01-0002
- LungFCP-01-0003
- LungFCP-01-0004
- LungFCP-01-0005
- LungFCP-01-0006

The folder “CT” contains the 3D CT volume saved as one mha file, the segmentation of the lesion obtained by majority voting for the three radiologist segmentations, and the segmentation of the blood vessels.

The folder “histology” has a similar content as the raw histology data, but a lower resolution, with some additional processing, e.g. applied gross rotation and flipping to correct for artifacts related to the mounting on the glass slide, and with additional annotations beside the lesion and in situ disease, e.g. blood vessels.

The folder Results contain the outcome of the registration of the histopathology images and the CT. All scripts used for generating these results are available at <https://github.com/mirabelarusu/RadPathFusionLung>

Please refer to the following publication for the methodological details:

Rusu M., Rajiah P., Gilkeson R., Yang M., Donatelli C., Thawani R., Jacono F.J., Linden P., Madabushi A. (2017) Co-registration of pre-operative CT with ex vivo surgically excised ground glass nodules to define spatial extent of invasive adenocarcinoma on in vivo imaging: a proof-of-concept study. *European Radiology* 27:10, 4209:4217. DOI: <https://doi.org/10.1007/s00330-017-4813-0>

Citations & Data Usage Policy

Citations & Data Usage Policy

Users of this data must abide by the [Creative Commons Attribution 3.0 Unported License](https://creativecommons.org/licenses/by/3.0/) under which it has been published. Attribution should include references to the following citations:

Data Citation

Madabhushi, A., & Rusu, M. (2018). Fused Radiology-Pathology Lung Dataset. The Cancer Imaging Archive. <https://doi.org/10.7937/K9/TCIA.2018.SMT36LPN>

Publication Citation

Rusu et al. Co-registration of pre-operative CT with ex vivo surgically excised ground glass nodules to define spatial extent of invasive adenocarcinoma on in vivo imaging: a proof-of-concept study. *European Radiology* (2018); PMID:PMC5630490 DOI:[10.1007/s00330-017-4813-0](https://doi.org/10.1007/s00330-017-4813-0)

TCIA Citation

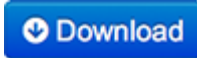


Clark K, Vendt B, Smith K, Freymann J, Kirby J, Koppel P, Moore S, Phillips S, Maffitt D, Pringle M, Tarbox L, Prior F. **The Cancer Imaging Archive (TCIA): Maintaining and Operating a Public Information Repository**, Journal of Digital Imaging, Volume 26, Number 6, December, 2013, pp 1045-1057. ([paper](#))

Other Publications Using This Data

TCIA maintains [a list of publications](#) that leverage our data. At this time we are not aware of any publications based on this data. If you have a publication you'd like to add, please [contact the TCIA Helpdesk](#).

Versions

Version 1 (Current) Updated 07-30-2018

Data Type	Download all or Query/Filter
Images (DICOM, 5.5 GB)	  (Requires the NBIA Data Retriever .)
Annotated Whole Slide Pathology Images (TIF, 21.3 GB)	
Clinical data (XLSX)	