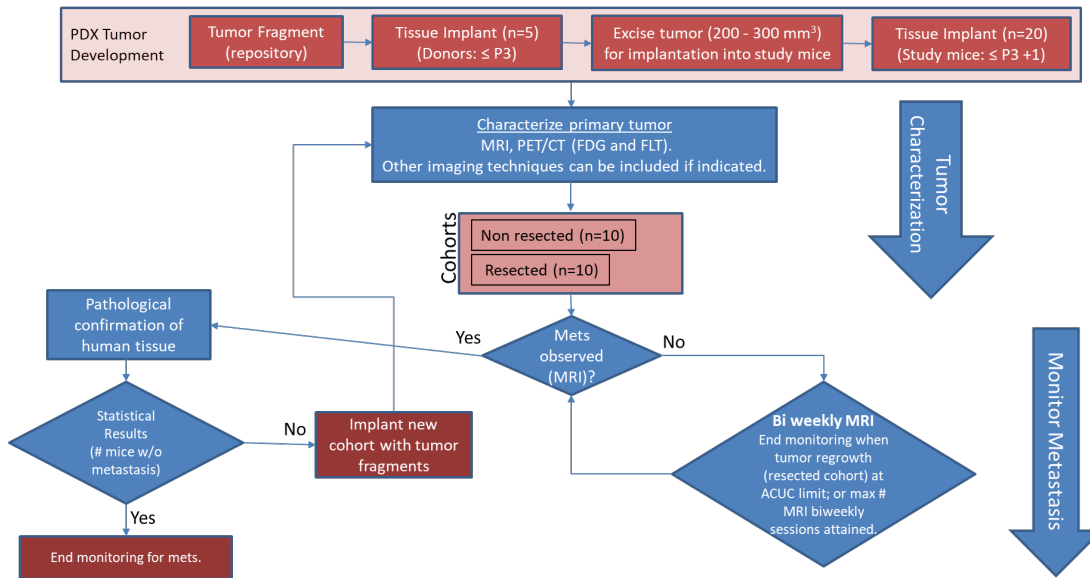


# Imaging characterization of a metastatic patient derived model of adenocarcinoma pancreas: PDMR-292921-168-R

# Summary

Pre-clinical animal models of spontaneous metastatic cancer are infrequent; the few that exist are resource intensive because determination of the presence of metastatic disease, metastatic burden, and response to therapy normally require multiple timed cohorts with animal sacrifice and extensive pathological examination. We identified and characterized a patient derived xenograft model with metastatic potential, adenocarcinoma pancreas xenograft 292921-168-R. In this study we performed a detailed imaging characterization (workflow below) of this model, which develops spontaneous lung metastases, details are provided in the attached standard operating procedures. Tumors in half of the mice were resected in the range 200-300 cm<sup>3</sup> size; tumors in the other half were allowed to grow until it was necessary to euthanize them because of tumor size.

## Workflow: Characterization of PDX primary tumor and metastasis



The imaging characteristics of this model (PDMR-292921-168-R), which is available from the National Cancer Institute Patient-Derived Models Repository (<https://pdmr.cancer.gov/>), is highly favorable for preclinical research studies of metastatic disease when used in conjunction with non-contrast T2 weighted MRI.

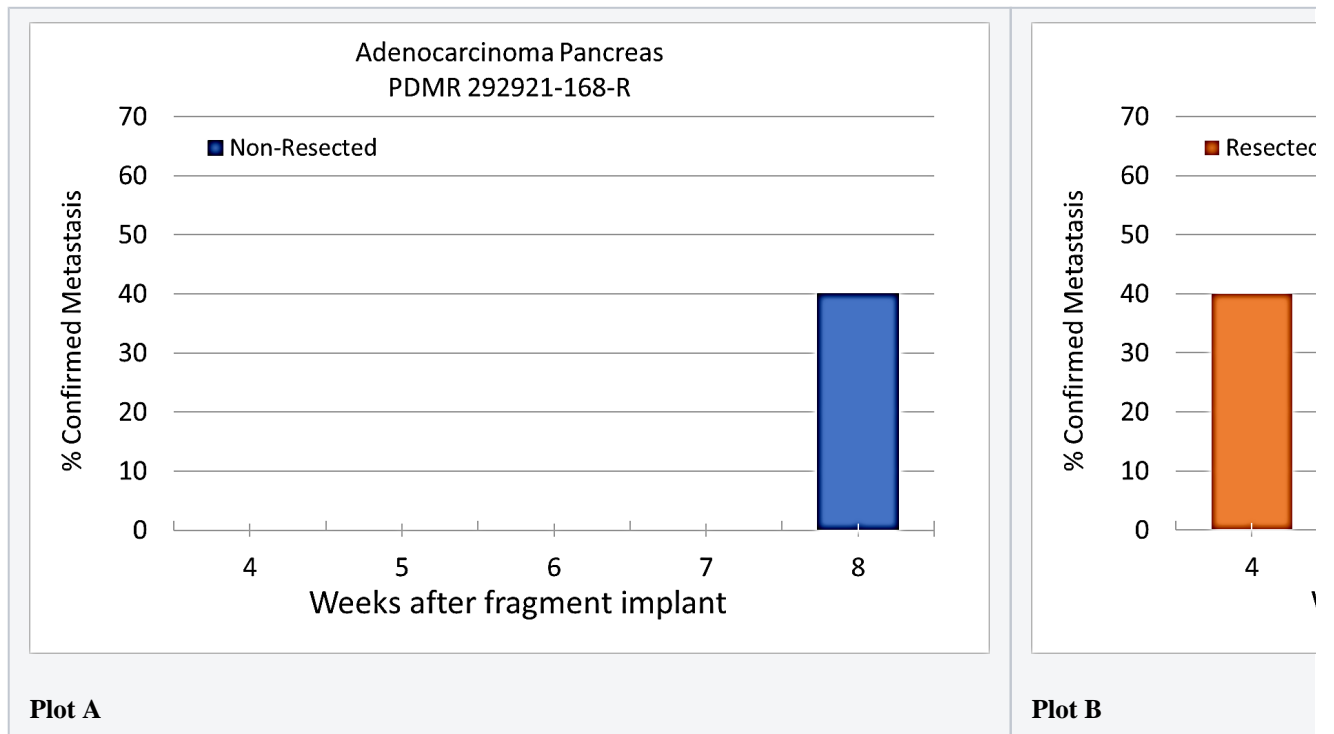
## Results: Adenocarcinoma pancreas (PDMR-292921-168-R)

**Table 1:** Penetrance and location of pathological confirmed metastatic lesion(s).

# animal s in Group	# animals that displayed metastasis in MRI and confirmed by Pathology	Pathology confirmation of MRI (primary imaging site)	Other confirmed Location (s)	Mouse ID: MRI with pathology confirmation of metastasis
10 (non-resected)	4 (5 mice were EU due to xenograft size prior to observation of metastases)	Lung	Lung	1409, 1410, 1418, 1423

10 (resected)	10	Lung	Lung, Kidney, Nodes, Peritoneal Wall	1405, 1407, 1408, 1411, 1413,1415, 1416, 1419, 1420, 1422
------------------	----	------	--	---

Percent penetrance with respect to the average time-to-metastasis for non-resected (**plot A**: time from implant) and resected (**plot B**: time from tumor resection) cohorts.



PET/CT Characterization of the primary tumor: Baseline PET (SOP available below) were performed when tumor reached an approximate 200 mm<sup>3</sup>. Average SUV<sub>max</sub> values (n=5) were calculated; [18F]FDG:  $1.3 \pm 0.2$  and [18F]FLT:  $2.3 \pm 0.6$ .

## Conclusion

Excellent metastatic model with at least 50% penetrance un-resected and 100% with planned early resection. Metastases are well observed on T2 MRI imaging allowing non-invasive evaluation in treatment trials.

## Acknowledgements






We would like to acknowledge the individuals and institutions that have provided data for this collection:

- Frederick National Laboratory for Cancer Research – Special Thanks to Joseph D. Kalen, PhD, Lilia V. Ileva, MS, Lisa A Riffle, Nimit Patel, Keita Saito, PhD, Yvonne Evrard, PhD, Elijah Edmondson, DVM, PhD, Jessica Phillips, Simone Difilippantonio, PhD, Chelsea Sanders, Amy James, Lia Thang, Ulrike Wagner, Yanling Liu, PhD, John B. Freymann, and Justin Kirby.
- Division of Cancer Therapeutics and Diagnosis/National Cancer Institute - James L. Tatum, MD, Paula M Jacobs, PhD, Melinda G. Hollingshead, DVM, and James H. Doroshow, MD
- PixelMed Publishing – Special Thanks to David A. Clunie, MD
- University of Arkansas for Medical Sciences – Special Thanks to Kirk E. Smith
- This project has been funded in whole or in part with Federal funds from the National Cancer Institute, National Institutes of Health, under Contract No. HHSN261201500003I. The content of this publication does not necessarily reflect the views or policies of the Department of Health and Human Services, nor does mention of trade names, commercial products, or organizations imply endorsement by the U.S. Government.

### Data Access

## Data Access

Click the **Download** button to save a ".tcia" manifest file to your computer, which you must open with the [NBIA Data Retriever](#) . Click the **Search** button to open our Data Portal, where you can browse the data collection and/or download a subset of its contents.

Data Type	Download all or Query/Filter
Images (DICOM, 1.6 GB)	  (Download requires <a href="#">NBIA Data Retriever</a> )
PDMR Patient Specimen (external)	
Standard Operating Procedure 50101: MRI T2 Weighted Non-Contrast Protocol: Single Mouse Pulmonary Gated and Multi-Mouse Non-Gated	
Standard Operating Procedure 50102: Positron Emission Tomography (PET) imaging protocol	

Click the Versions tab for more info about data releases.

### Detailed Description

## Detailed Description

Image Statistics	
Modalities	MR, SR
Number of Subjects	20
Number of Studies	89
Number of Series	160

Number of Images	2657
Images Size (GB)	1.6 GB

### Citations & Data Usage Policy

## Citations & Data Usage Policy

Users of this data must abide by the [Creative Commons Attribution 4.0 International License](#) under which it has been published. Attribution should include references to the following citations:

### **i** Data Citation

Tatum, J., Kalen, J., Ileva, lilia, L, R., S, K., N, P., Jacobs, P., Sanders, C., A, J., Difilippantonio, S., L, T., hollingshead, melinda, J, P., Y, E., Clunie, D., Y, L., Suloway, C., Smith, K., U, W., ... Doroshov, J. (n.d.). Imaging characterization of a metastatic patient derived model of adenocarcinoma pancreas: PDMR-292921-168-R. The Cancer Imaging Archive. <https://doi.org/10.7937/TCIA.2020.PCAK-8Z10>

### **i** Acknowledgement

This project has been funded in whole or in part with Federal funds from the National Cancer Institute, National Institutes of Health, under Contract No. HHSN261201500003I. The content of this publication does not necessarily reflect the views or policies of the Department of Health and Human Services, nor does mention of trade names, commercial products, or organizations imply endorsement by the U.S. Government.

### **i** TCIA Citation




Clark K, Vendt B, Smith K, Freymann J, Kirby J, Koppel P, Moore S, Phillips S, Maffitt D, Pringle M, Tarbox L, Prior F. **The Cancer Imaging Archive (TCIA): Maintaining and Operating a Public Information Repository**, Journal of Digital Imaging, Volume 26, Number 6, December, 2013, pp 1045-1057. DOI: [10.1007/s10278-013-9622-7](https://doi.org/10.1007/s10278-013-9622-7)

## Other Publications Using This Data

TCIA maintains [a list of publications](#) which leverage TCIA data. If you have a manuscript you'd like to add please [contact the TCIA Helpdesk](#).

### Versions

## Version 1 (Current): Updated 2020/03/23

Data Type	Download all or Query/Filter
Images (DICOM, 1.6 GB)	<div style="text-align: right;">                 (Requires <a href="#">NBIA Data Retriever</a> .)         </div>
PDMR Patient Specimen (external)	<div style="text-align: right;">  </div>

SOP50101: MRI T2 Weighted Non-Contrast Protocol: Single Mouse Pulmonary Gated and Multi-Mouse Non-Gated

 Download