

Soft-tissue-Sarcoma

Summary

This collection contains FDG-PET/CT and anatomical MR (T1-weighted, T2-weighted with fat-suppression) imaging data from 51 patients with histologically proven soft-tissue sarcomas (STSs) of the extremities. All patients had pre-treatment FDG-PET/CT and MRI scans between November 2004 and November 2011. (Note: date in the TCIA images have been changed in the interest of de-identification; the same change was applied across all images, preserving the time intervals between serial scans). During the follow-up period, 19 patients developed lung metastases. Imaging data and lung metastases development status were used in the following study:

Vallières, M. et al. (2015). A radiomics model from joint FDG-PET and MRI texture features for the prediction of lung metastases in soft-tissue sarcomas of the extremities. *Physics in Medicine and Biology*, 60(14), 5471-5496. doi:10.1088/0031-9155/60/14/5471.

Imaging data, tumor contours (*RTstruct* DICOM objects), clinical data and source code is available for this study. See the DOI below for more details and links to access the whole dataset. Please [contact the TCIA Helpdesk](#) for any scientific or other inquiries about this dataset.

Acknowledgements





We would like to acknowledge the individuals and institutions that have provided data for this collection:

- **McGill University, Montreal, Canada** - Special thanks to **Martin Vallières** of the Medical Physics Unit

Data Access

Data Access

Click the **Download** button to save a ".tcia" manifest file to your computer, which you must open with the [NBIA Data Retriever](#). Click the **Search** button to open our Data Portal, where you can browse the data collection and/or download a subset of its contents.

Data Type	Download all or Query /Filter
Images and Radiation Therapy Structures (DICOM, 9.9GB)	 
Clinical Data (XLS)	
Source Code (web)	

Click the Versions tab for more info about data releases.

Detailed Description

Detailed Description

Collection Statistics	
Modalities	FDG-PET/CT, MR, RTSTRUCT
Number of Participants	51
Number of Studies	102
Number of Series	612
Number of Images	38,283
Images Size (GB)	9.9

In this study, a cohort of 51 patients with histologically proven soft-tissue sarcomas (STSs) of the extremities was retrospectively evaluated. All patients had pre-treatment FDG-PET/CT and MRI scans between November 2004 and November 2011 (Note: date in the TCIA images have been changed in the interest of de-identification; the same change was applied across all images, preserving the time intervals between serial scans). During the follow-up period, 19 patients developed lung metastases. Patients with metastatic and/or recurrent STSs at presentation were excluded from the study.

The FDG-PET scans were performed on a PET/CT scanner (Discovery ST, GE Healthcare, Waukesha, WI) at the McGill University Health Centre (MUHC). A median of 420 MBq (range: 210-620 MBq) of FDG was injected intravenously. Approximately 60 min following the injection, whole-body 2D imaging acquisition was performed using multiple bed positions, with a median of 180 s (range: 160-300 s) per bed position. PET attenuation corrected images were reconstructed (axial plane) using an ordered subset expectation maximization (OSEM) iterative algorithm. The MRI scans resulted from clinical acquisitions with non-uniform protocols across patients. Twelve patients had their images acquired at the MUHC, and 39 in an outside institution. Three types of MRI sequences routinely used in clinical protocols were selected for the study, namely T1-weighted (T1), T2-weighted fat-saturated and short tau inversion recovery (STIR) sequences. T1 sequences were acquired in the axial plane for all patients. On the other hand, patients were scanned in different planes with either or both T2-weighted fat-saturated and STIR sequences, which macroscopically are both T2-weighted sequences aiming to suppress the fat signal in the body. From a texture point of view, T2-weighted fat-saturated and STIR images are considered similar, and they were thus combined in the same scan category with only one of the two sequences used per patient. T2-weighted fat-saturated scans were selected by default due to their higher axial scan availability ($n = 26$). When T2-weighted fat-saturated scans were not available, STIR scans were used ($n = 25$). For the rest of this text, this category of scans is referred to as T2FS (T2-weighted fat-suppression) scans.

Contours defining the 3D tumour region for each patient were manually drawn slice-by-slice on T2FS scans by an expert radiation oncologist. For patients with visible edema in the vicinity of the tumours ($n = 32$), two contours were drawn: one excluding the visible edema ("GTV_Mass") and one incorporating it ("GTV_Edema"). Contours were propagated to FDG-PET and T1 scans using rigid registration with the commercial software MIM[®] (MIM software Inc., Cleveland, OH). In this dataset, these contours are available as *RTstruct* DICOM objects for all scans of all patients.

In our work, we developed a joint FDG-PET and MRI texture-based model for the early evaluation of lung metastasis risk in STSs. We explored a novel approach based on the fusion of FDG-PET and MRI volumes to better quantify intratumoural heterogeneity using texture analysis. Fusion was implemented using a technique based on the wavelet transform, by first registering and resampling MRI volumes onto FDG-PET volumes (registered/resampled MRI data is also available in this dataset). Nine non-texture features (SUV metrics and shape features) and multiple variations of 41 texture features were extracted from the tumour region of separate (FDG-PET, T1 and T2FS) and fused (FDG-PET/T1 and FDG-PET/T2FS) scans as defined by the *GTV_Mass* contours of the *RTstruct* objects. The textures extracted from the *GTV_Edema* contours were used to evaluate the uncertainty of our model due to segmentation variations. The results showed that FDG-PET and MRI texture features could act as strong prognostic factors of STSs and could provide insights about their underlying biology. Ultimately, we identified a model combining four texture features extracted from fused FDG-PET/MRI pre-treatment scans to predict future lung metastases development in STSs. Innovative texture extraction techniques and multivariable modeling strategies were also developed for the construction of tumour outcome prediction models from a large number of *radiomics* features. We believe that the methodology presented in this work could be generalized to other cancer types and that it could eventually lead to improvements in treatment personalization and patient survival. However, much effort is still required in order to achieve clinical implementation of a texture-based decision-support system. A consensus on techniques used for imaging acquisition, data pre-processing, tumour delineation, texture analysis and multivariable modeling is first needed, and we hope the available data and source code will facilitate the standardization of methods in the *radiomics* community.

- **Clinical Data** – This spreadsheet includes patient information, histopathological type, tumour grade, outcome follow-up information (metastases, survival), etc.: [INFOclinical_STS.xlsx](#)
- **Source Code** – All software code implemented in this work is freely shared under the GNU General Public License at: <https://github.com/mvallieres/radiomics>. See the function 'readAllDICOM_STS.m' to read and organize the DICOM data in MATLAB.

Note: the images contain no private-vendor DICOM tags.

Citations & Data Usage Policy

Citations & Data Usage Policy

Users of this data must abide by the [TCIA Data Usage Policy](#) and the [Creative Commons Attribution 3.0 Unported License](#) under which it has been published. Attribution should include references to the following citations:

Data Citation

Vallières, Martin, Freeman, Carolyn R., Skamene, Sonia R., & El Naqa, Issam. (2015). A radiomics model from joint FDG-PET and MRI texture features for the prediction of lung metastases in soft-tissue sarcomas of the extremities. The Cancer Imaging Archive. <http://doi.org/10.7937/K9/TCIA.2015.7GO2GSKS>

Publication Citation

Vallières, M., Freeman, C. R., Skamene, S. R., & Naqa, I. El. (2015, June 29). A radiomics model from joint FDG-PET and MRI texture features for the prediction of lung metastases in soft-tissue sarcomas of the extremities. Physics in Medicine and Biology. IOP Publishing. <http://doi.org/10.1088/0031-9155/60/14/5471>

TCIA Citation

Clark K, Vendt B, Smith K, Freymann J, Kirby J, Koppel P, Moore S, Phillips S, Maffitt D, Pringle M, Tarbox L, Prior F. **The Cancer Imaging Archive (TCIA): Maintaining and Operating a Public Information Repository**, Journal of Digital Imaging, Volume 26, Number 6, December, 2013, pp 1045-1057. ([paper](#))



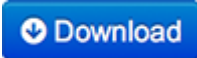
Other Publications Using This Data

TCIA maintains [a list of publications](#) which leverage our data. At this time we are not aware of any publications based on this data. If you have a publication you'd like to add please [contact the TCIA Helpdesk](#).

Versions

Version 1 (Current): Updated 2015/06/01

Downloads require the [NBIA Data Retriever](#) .

Data Type	Download all or Query/Filter
Images (DICOM, 9.9GB)	 
Clinical Data (XLS)	
Source Code (web)	